

IMAGE OF THE MOMENT

Xanthochromia in the cerebrospinal fluid

Anna Williams

Department of Clinical Neurosciences,
Western General Hospital, Crewe Road, Edinburgh, EH4 2XU;
E-mail: acw@skull.dcn.ed.ac.uk
Practical Neurology, 2004, 4, 174–175

Although a CT brain scan within 12 h of the onset of headache confirms the diagnosis in about 98% of subarachnoid haemorrhage (SAH) patients (Van der Wee *et al.* 1995), blood is visible in only about 50% a week later (Van Gijn & Van Dougen 1982). Clearly therefore some patients with a sudden onset headache and a normal CT brain scan may still have had an SAH, particularly if the scan is delayed. Detecting the final few cases is important because a missed aneurysmal SAH can be fatal if a recurrent bleed occurs, and clipping or coiling will prevent this.

The standard follow-on test after a negative CT is evidence of blood in the cerebrospinal fluid (CSF). Any test must be sensitive enough to pick up cases of aneurysmal SAH and so allow timely intervention, but specific enough not to expose too many patients to the risk of unnecessary tests, particularly catheter angiograms.

The word 'xanthochromia' is derived from the Greek meaning yellow. It can be seen in patients with a high CSF protein, jaundice or carotene addiction. However, in a patient with sudden headache, it is suggestive of subarachnoid blood either as part of an inflammatory reaction such as meningitis, or after SAH. Thus any 'xanthochromia' must be viewed within the appropriate clinical context.

There are two ways to detect CSF xanthochromia. Clear, yellow fluid can often be seen on visual inspection (Fig. 1). However, spectrophotometry increases the sensitivity of the test, detecting 'yellow' that is not discernible to the human eye, and it can distinguish different pigments by their different absorption of light (Fig. 2).

When red blood cells in the CSF haemolyse, they release oxyhaemoglobin, which can be detected within 4–10 h of a bleed, at a wavelength of 415 nm (Barrows *et al.* 1955). The enzyme haem oxidase, which is found in macrophages, the arachnoid membrane and the choroid plexus, then converts oxyhaemoglobin into bilirubin, detected at 450–460 nm. The time course for this conversion is uncertain. It has been reported to be 9–10 h (Fishman 1980), after 24 h (Wahlgren & Lindquist 1987) or at 3–4 days (Barrows *et al.* 1955). In practice, doctors generally delay CSF examination in CT-negative patients with sudden headache by 12 h from the onset to 'allow' the yellow colour to develop. This is because in one study of 111 patients with CT-positive SAH, they all had 'xanthochromia' on spectrophotometry at 12 h until 7 days after the onset (Vermeulen *et al.* 1989). However, this is clearly a different group from CT-negative patients, either because so little blood has been



Figure 1 Visual examination of CSF showing xanthochromia in one bottle.

released in the head, or because the scan has been done 'late'.

A traumatic tap introduces red blood cells into the CSF, which can also haemolyse, forming oxyhaemoglobin. But this is *not* converted into bilirubin in the CSF sample once it has been collected. Thus the presence of CSF bilirubin is a more specific test for true subarachnoid blood than oxyhaemoglobin.

Xanthochromia has been defined as an absorbance at 415 nm of greater than 0.023AU (absorbance units) and/or a peak in the absorbance curve in the 450–460 nm region (Vermeulen *et al.* 1989). These authors believed that the presence of either oxyhaemoglobin or bilirubin was sufficient to define xanthochromia, and the level of 0.023AU detected all their cases with SAH. But because traumatic taps can produce oxyhaemoglobin this definition is disputed.

A working group for the UK National External Quality Assessment Scheme for Immunohistochemistry recently published guidelines for spectrophotometric analysis of CSF in suspected SAH (UK NEQAS 2003). Here, the diagnosis of SAH is based on a 'net bilirubin absorbance' of more than 0.007AU. High oxyhaemoglobin absorbance alone is thought unlikely to be due to SAH, and is reported as inconclusive. These guidelines may lead to standard analysis and reporting but are based on biochemical measurements and give no data for the sensitivity or specificity of either measurement in detecting SAH in patients.

Exactly what measurement is clinically relevant in patients with a CT-negative sudden headache is still unanswered. All spectrophotometric information to date has been derived from patients with CT visible subarachnoid blood, and their heavier blood load may make these pigments easier to detect and prolong the time course of detectable pigment production. However, detection of bilirubin in the CSF would certainly raise strong suspicions of SAH, and the absence of pigments in the CSF would be very reassuring evidence against SAH. The middle ground is more murky, with no data indicating the likelihood of SAH from aneurysm rupture in patients who only have oxyhaemoglobin in the CSF. We know the risk is low, but we are not sure how low. But the risk of a catheter angiogram is also low, and the risk from a repeat aneurysmal SAH is high.

In a CT-negative patient, the gold standard for diagnosis of aneurysmal SAH is the presence of an aneurysm on imaging, which is likely to

have ruptured rather than being an innocent unruptured bystander. Although difficult, it would be helpful to survey the risk of later aneurysmal haemorrhage in those with and without a 'positive' test for xanthochromia so that the sensitivity and specificity of the test could be determined. In the meantime practice varies, and we muddle along.

REFERENCES

- Barrows LJ, Hunter FT & Banker BQ (1955) The nature and significance of pigments in the cerebrospinal fluid. *Brain*, **78**, 59–80.
- Fishman RA (1980) *Cerebrospinal Fluid in Diseases of the Nervous System*. London: W.B. Saunders Co.
- UK National External Quality Assessment Scheme for Immunohistochemistry Working Group (2003) Title. *Annals of Clinical Biochemistry*, **40**, 481–8.
- Van der Wee N, Rinkel GJE, Hasan D & Van Gijn J (1995) Detection of subarachnoid haemorrhage on early CT: is lumbar puncture still needed after a negative scan? *Journal of Neurology, Neurosurgery and Psychiatry*, **58**, 357–9.
- Van Gijn J & Van Dougen KJ (1982) The time course of aneurysmal haemorrhage on computed tomograms. *Neuroradiology*, **23**, 153–6.
- Vermeulen M, Hasan D, Blijenberg BG, Hijdra A & Van Gijn J (1989) Xanthochromia after subarachnoid haemorrhage needs no revisitation. *Journal of Neurology, Neurosurgery and Neuropsychiatry*, **52**, 826–8.
- Wahlgren NG & Lindquist C (1987) Haem derivatives in the cerebrospinal fluid after intracranial haemorrhage. *European Neurology*, **26**, 216–21.

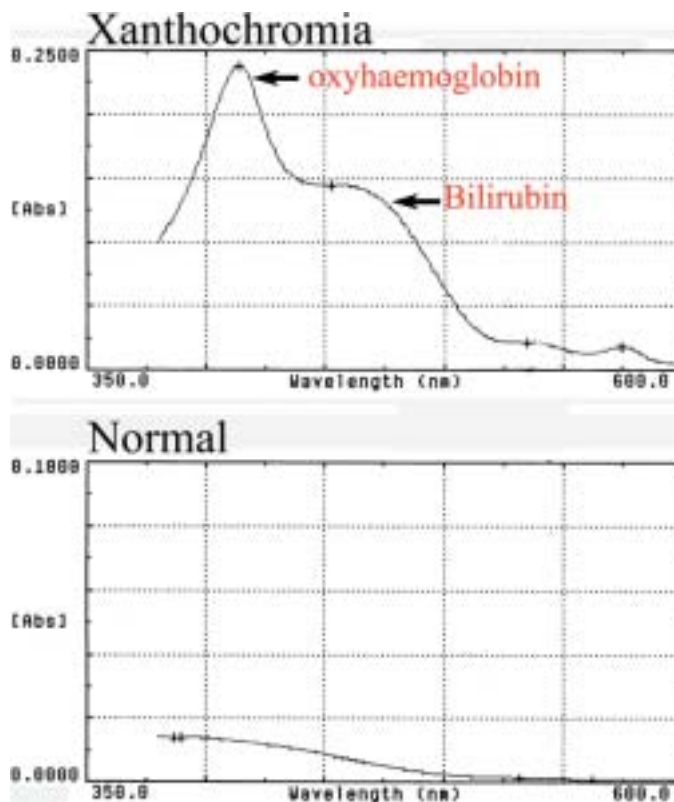


Figure 2 Spectrophotometric scans of the fluid shown in Fig. 1. The oxyhaemoglobin and bilirubin peaks are marked. The y-axis shows the absorbance in standardized absorbance units (AU).